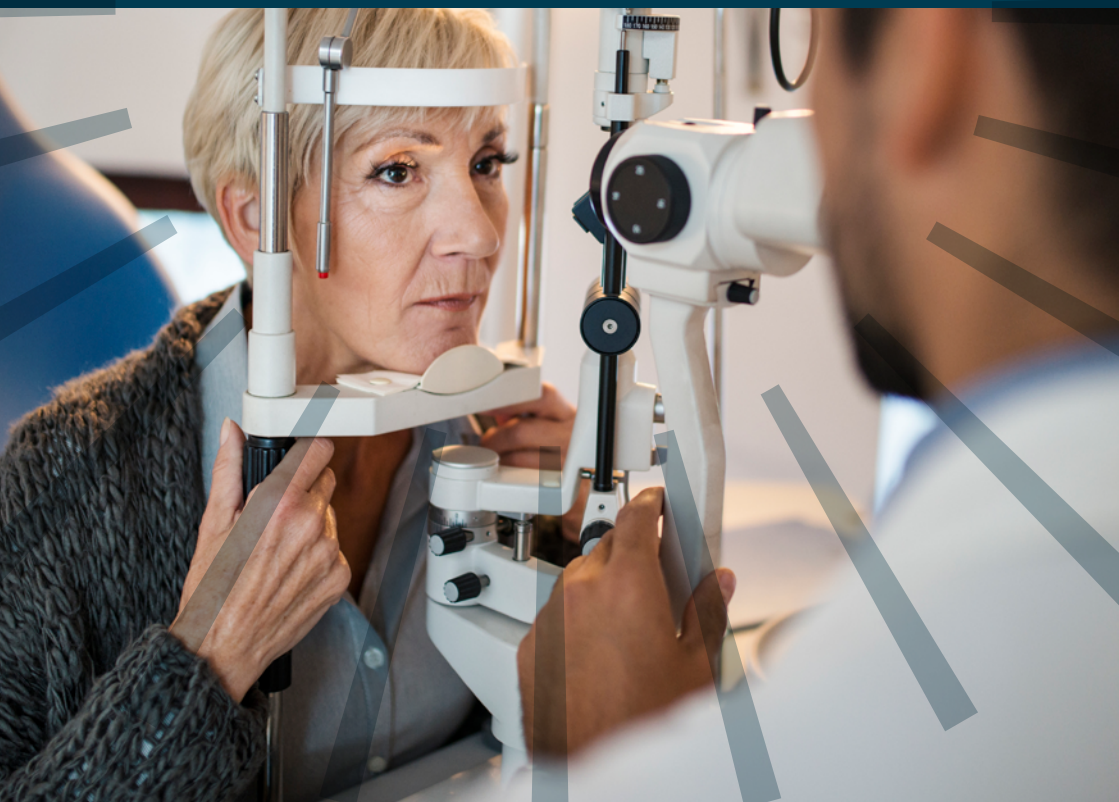

# Secondary Glaucomas



This free booklet is brought to you by **Glaucoma UK**  
(formerly the International Glaucoma Association).  
Contact Glaucoma UK for further information or advice:

**Glaucoma helpline:** 01233 64 81 70

Monday-Friday 9.30am-5.00pm

**Email:** [helpline@glaucoma.uk](mailto:helpline@glaucoma.uk)

**[glaucoma.uk](http://glaucoma.uk)**

**Author: Mr Hari Jayaram MA MSc PhD FRCSEd**

Consultant Ophthalmologist, Glaucoma Service,  
Moorfields Eye Hospital

**Medical Editor: Mr Nick Strouthidis MBBS MD PhD FRCS  
FRCOphth FRANZCO**

Consultant Ophthalmic Surgeon Medical Director  
Moorfields Eye Hospital

Charity registered in England and Wales  
No. 274681 and Scotland No. SC041550

**Glaucoma UK is a registered charity that is here for everyone living with glaucoma throughout the UK.**

- We raise awareness of glaucoma so that it is detected and treated early.
- We campaign for effective services for everyone affected by glaucoma.
- We provide advice and support to help people live well with glaucoma.
- We fund vital glaucoma research.



**Campaigning  
& Awareness**

Fewer  
people  
go blind



**Advice &  
Support**

People with  
glaucoma live well  
and stay well



**Research**

Better  
diagnosis,  
care and  
treatment

# Contents

<b>01</b>	<b>Introduction: What is Glaucoma?</b>	<b>3</b>
<b>02</b>	<b>Causes of Secondary Glaucoma</b>	<b>7</b>
	Pigment dispersion syndrome and pseudoexfoliation	7
	Iatrogenic	8
	Inflammation in the eye (uveitic glaucoma)	9
	Lens-related problems	11
	Trauma	13
	Medicine-related	14
	Neovascular (newly formed blood vessels)	15
	Following corneal disease and corneal surgery	15
	Iridocorneal endothelial (ICE) syndrome	16
	Bleeding inside the eye	17
	Raised Episcleral Venous Pressure	17
	Tumours	18
<b>03</b>	<b>Treatment</b>	<b>19</b>
<b>04</b>	<b>Remember</b>	<b>22</b>
<b>05</b>	<b>Questions you could ask your eye consultant</b>	<b>23</b>
<b>06</b>	<b>Further information and help from Glaucoma UK</b>	<b>24</b>

# 01

## Introduction: What is glaucoma?

Glaucoma is the name given to a number of conditions in which the optic nerve is damaged. The optic nerve transmits vision from the eye to the brain. Glaucoma damage in the optic nerve has a characteristic appearance and can affect the vision, causing progressive visual loss if untreated. Many eyes that develop glaucoma have raised intraocular pressure (high pressure in the eye) but there are other factors that may influence the development of glaucoma damage such as poor blood supply to the optic nerve and weakness of the connective tissues supporting the optic nerve. A proportion of patients who develop glaucoma may therefore never have high pressure, although at present the treatment remains the same, which is to lower the eye pressure.

### What is secondary glaucoma?

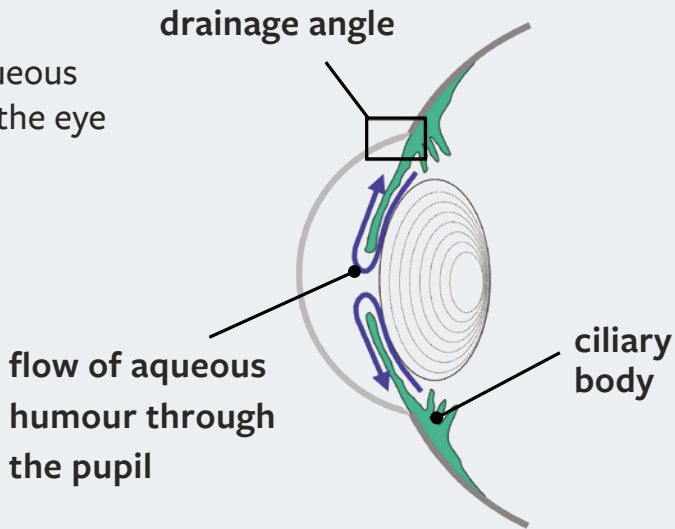
In most cases, glaucoma is of a 'primary' form, meaning that there is no identifiable cause for high pressure or the development of glaucoma. A 'secondary' glaucoma, on the other hand, occurs where there is an underlying ophthalmic or medical condition that predisposes to the development of high eye pressure.

The front part of the eye (anterior chamber) is bathed

in a clear watery fluid called aqueous humour, usually shortened to ‘aqueous’. This fluid keeps the eyeball firm and also nourishes the important tissues within the front part of the eye. The aqueous is produced by a structure called the ciliary body, located behind the pupil and lens. The aqueous passes through the pupil, which is the central hole in the coloured part of the eye (iris). It then circulates in the anterior chamber between the clear window at the front of the eye (cornea) and the iris.

### Figure 1

Flow of aqueous humour in the eye

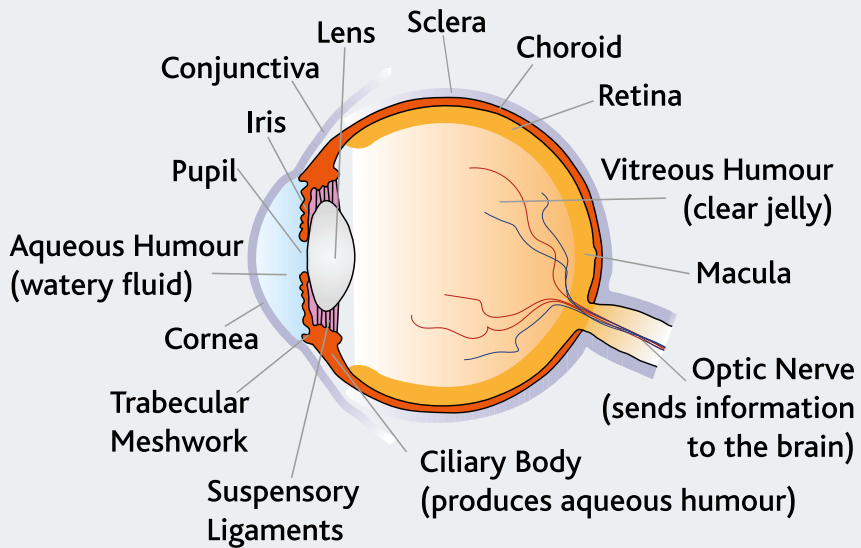


Aqueous production is continuous but drops down to a minimum at night. If there was no mechanism for the aqueous to drain out of the eye, the pressure in the eye would become too high. There is therefore a drainage

system called the trabecular meshwork located in the angle formed by the cornea and the iris. Once the aqueous drains through the trabecular meshwork it enters into the bloodstream. In secondary glaucoma, there is some form of impairment to the drainage system, with an identifiable underlying cause.

## Figure 2

Cross section through the eye showing the major structures, [Health Press Unlimited \(Oxford\)](#)



There are several reasons why a patient might be diagnosed with secondary glaucoma. There may be a disorder present locally in the eye, a general disease or

the use of medication which is, or has been, the cause or a contributory cause of raised eye pressure. Strictly speaking, the condition is called 'secondary ocular hypertension' if there is just raised intraocular pressure but with no detectable damage to the optic nerve. If, however, the raised pressure damages the optic nerve, which therefore can lead to visual loss, this would then be called secondary glaucoma.

Secondary glaucoma is unlike primary open angle glaucoma, in that when the underlying problem causing raised intraocular pressure is corrected or cured (if this is possible), the pressure may return to normal and further medication may be unnecessary. Unfortunately, existing damage to either the optic nerve or visual field cannot be reversed, but should stabilise once the pressure is normalised.

The good thing about secondary glaucomas is the fact that reversal or treatment of the underlying cause will often normalise the pressure and could possibly cure the glaucoma.

Most secondary glaucomas will require treatment of the underlying cause, drops to lower the pressure (and possibly tablets in the short-term) and anti-inflammatory drops if there is an inflammatory component.

There are certain circumstances where surgical or laser treatments are required and these are discussed in the treatment section later in this booklet.



## 02 Causes of secondary glaucoma



### 1. Pigment dispersion syndrome and pseudoexfoliation

These are two of the commonest causes of secondary open angle glaucoma. Because they are treated in an identical fashion to primary open angle glaucoma, some doctors classify them as part of the same condition

(‘chronic open angle glaucoma’). In pigment dispersion syndrome, pigment granules are intermittently rubbed off the back of the iris as it moves and touches the lens and these granules become deposited in the trabecular meshwork. This causes a blockage to the drainage system which leads to high intraocular pressure. When it causes optic nerve damage it is termed pigmentary glaucoma. The condition is commoner in young, myopic (short-sighted) men.

In pseudoexfoliation, the trabecular meshwork gets clogged up with white flakes. These flakes are deposits from the surface of the lens capsule, rather like dandruff, that get shed by the continuous movement of the iris (when the pupil gets larger or smaller). If pseudoexfoliation leads to damage to the optic nerve it is termed pseudo-exfoliative glaucoma. It tends to be more common with increasing age and is thought to be more prevalent in certain ethnic groups (such as those of Scandinavian and Southern Mediterranean descent), although can be seen in any ethnicity.

## 2. Iatrogenic

Iatrogenic literally means ‘caused by a doctor’ and unfortunately this is perhaps the most common presentation of true secondary ocular hypertension seen in eye clinics. The main iatrogenic cause is following retinal surgery. This is because sometimes the retinal surgeon needs to put substances such as gas or silicone oil in the eye in order to flatten the retina following a retinal

detachment or after other retinal surgical treatments. These substances invariably cause the pressure to rise and sometimes the rise in pressure can be very high. With gas, the effect is usually short-term and some of the gas may be removed early to reduce the pressure. Silicone oil may need to stay inside the eye for many months, years or indefinitely and a high proportion of these patients may develop secondary glaucoma.

Another common ‘iatrogenic’ cause for high pressure is the use of steroids – in the form of tablets, face creams, nasal sprays and, in some cases, extended use of steroid eye drops. Other medications can cause high pressure by a number of different mechanisms. Drug causes of secondary glaucoma will be discussed in a separate section.

### **3. Inflammation in the eye (uveitic glaucoma)**

Uveitis is inflammation of the layer of pigmented tissues inside the eye (uvea, made up of the iris, ciliary body, and choroid). There are a number of different ways in which uveitis can present – anterior uveitis or iritis will only affect the front of the eye, vitritis is inflammation in the vitreous, and posterior uveitis which is inflammation in the back of the eye.

There are a number of different mechanisms by which uveitis can cause high pressure.

Uveitis may cause leakage of protein and white blood cells

into the aqueous, and these can deposit in the trabecular meshwork, blocking the drainage system.

The trabecular meshwork can become inflamed itself, a term called 'trabeculitis', blocking the spaces in the drainage system through which aqueous normally leaves the eye. The current common thinking amongst eye specialists is that this may increase pressure when the eye already has high pressure but only very minimal inflammation, such as the condition known as 'Posner-Schlossman syndrome' or when shingles affects the eye).

Uveitis may cause secondary angle closure. This is due to the fact that inflammation in the front part of the eye can cause the iris to stick to other structures. In the acute setting, the iris around the pupil can stick to the lens (posterior synechiae); if the pupil gets completely stuck down for 360 degrees then the aqueous cannot pass from the ciliary body to the anterior chamber. This means that aqueous builds up behind the iris, pushing it forwards and completely closing off drainage through the trabecular meshwork. This causes the pressure to go very high quickly and will require urgent intervention.

The pressure can be relieved by making a hole (iridectomy) in the iris to allow the aqueous to pass. This is preferably achieved using a surgical procedure, but laser can be used as a temporary measure in an emergency setting. When uveitis occurs over a long period of time, the iris can stick to the trabecular meshwork (peripheral

anterior synechiae) and if these adhesions are extensive there will be a significant reduction in aqueous outflow, leading to high pressure and glaucoma. Often the treatment for this will need to be surgical drainage.

One of the commonest causes of high pressure in uveitis is secondary to steroid treatment. This is discussed in more detail in a later section.

When high pressure occurs during an acute episode of anterior uveitis, it is usually termed ‘hypertensive uveitis’. A rare variant of this, when the pressure is very high but the inflammation is minimal, is called ‘Posner-Schlossman’ syndrome. In most cases, the episodes are short-lived and respond well to topical steroids to treat the inflammation and glaucoma medications (eye drops and occasionally Diamox tablets) to lower the eye pressure. The medications can usually be stopped once the episode has resolved. In some patients, the episodes can recur or eventually stop completely. However, in some patients who get frequent sustained episodes of high pressure, the optic nerve may become progressively damaged leading to glaucoma. These patients usually need long term treatment and in some cases surgery.

**Fuch’s Heterochromic Cyclitis** is a specific form of uveitis associated with loss of pigment from the iris of the eye, which becomes blue if previously brown. Symptoms are often absent in the early stages but raised pressure and cataract development may occur later and affect vision.

## 4. Lens-related problems

Cataracts may cause a secondary rise in pressure through an angle closure mechanism. When a cataract is very advanced it can become swollen and block the flow of aqueous from the ciliary body through the pupil. This causes a build up of aqueous behind the iris, pushing the iris forward, and closing off drainage through the trabecular meshwork. This type of mechanism is termed 'phacomorphic' and is relieved by removing the cataract. A similar 'pupil block' mechanism may occur if the lens within the eye is unstable due to weakness or loss of the ligaments that support the lens (known as zonules). This can happen following trauma and in patients with pseudoexfoliation (where the zonules are weaker than normal).

Very rarely, when a patient has advanced cataract, proteins from within the lens can leak into the aqueous and this can cause high pressure in the same way as with uveitic glaucoma. This mechanism is termed 'phacolytic' and will respond to removal of the cataract. Much more rarely, if there is a break in the capsule surrounding the lens (for example following an injury), leakage of lens material may cause a severe reaction in the eye causing a lot of inflammation and secondary raised pressure. This is termed 'phacoanaphylaxis' and once again requires removal of the cataract.

Occasionally secondary ocular hypertension occurs due to the position of the artificial lens inserted into the

eye during cataract surgery. Occasionally the lens must be inserted in the anterior chamber, rather than the posterior chamber. This mostly happens when there isn't enough support for an artificial lens within the remaining lens capsule (where lenses are usually inserted) following complicated cataract surgery. Some lenses used for refractive surgery are inserted into the anterior chamber. These lenses may block aqueous passage through the pupil causing a secondary angle closure. It is therefore essential that a peripheral iridectomy (a hole in the peripheral iris) is made when the lens is inserted. In these cases, the eye pressure can become very high if the peripheral iridectomy has not been made or closes off.

Sometimes, during complicated cataract surgery, the artificial lens is inserted behind the iris but in front of the capsule (in the 'sulcus'). The artificial lens in this position can occasionally rub pigment off the back of the iris and cause secondary pigment dispersion. This pigment can block the trabecular meshwork, leading to high eye pressure. If this problem is identified early, it can be reversed with removal or re-positioning of the lens. If the problem has been present for a long time the pigment will have caused permanent damage to the trabecular meshwork so removal or repositioning of the lens alone may not lower the pressure. This may require surgery to improve drainage.

Occasionally patients have cataracts removed and do not have an artificial lens inserted. This is called 'aphakia' and

it can cause a secondary glaucoma, although the precise mechanism is unknown. This is the most common cause of secondary glaucoma in children.

## 5. Trauma

A blow to the eye or a penetrating injury may cause high pressure through uveitis, haemorrhage (with blood cells clogging up the drainage system) or damage to the lens (such as dislocation or instability of the lens or capsule breaks as discussed above)

A chemical injury (such as an alkali burn) can lead to severe inflammation of the cornea and uveitis, leading to secondary raised pressure

Blunt trauma to the eye may cause the drainage angle to be pushed backwards permanently (angle recession). This can lead to the development of high pressure up to a number of years after the injury. Most patients found to have significant angle recession following an injury will be monitored for a number of years to ensure they do not develop glaucoma.

## 6. Medicine-related

The most common medicine-related cause of secondary raised intraocular pressure is called 'steroid response'. This is due to the use of steroids which may be inhaled, taken orally, injected, used on the skin or taken locally in the eye. Raised pressure caused by the steroid response is most common when the steroid is applied locally to the



eye, either via injection into or around the eye, or via a steroid eye drop. In most cases of steroid response, the intraocular pressure may reduce back to baseline levels if the steroid is withdrawn. It is important not to use steroid eye drops for a long time without having the eye pressure checked intermittently.

Sometimes steroids may be necessary for long periods for the treatment of uveitis or other ocular inflammatory conditions. It is increasingly common to inject steroid into the eye or to insert a long-acting steroid implant. The steroid-related pressure increase may be very prolonged in these cases and may require surgery to improve drainage.

In people with narrow drainage angles, any eye drop which dilates the pupil may result in raised pressure by closing the angle further.

## **7. Neovascular (newly formed blood vessels)**

In certain retinal conditions, such as proliferative diabetic retinopathy and central retinal vein occlusions, the poor blood supply within the eye may cause new blood vessels to grow onto the surface of the eye and into the drainage angle. The presence of the new vessels in the angle can cause the pressure to rise. If the new vessels become extensive and are present for a long time they can scar and completely close the drainage angle (synechial closure).

If detected early, treatment of the underlying retinal

condition may reverse the development of the new vessels and lower the pressure. If the angle has become completely closed, the high pressure may not respond adequately to drop treatment, so glaucoma drainage surgery or cyclodiode laser is usually required.

Often patients will already have poor vision in the affected eye due to the underlying retinal problem. However, if the pressure and the underlying retinal condition treated are not adequately treated quickly enough, the secondary glaucoma due to the new vessels (also called rubeotic glaucoma) can lead to severe optic nerve damage with a high risk of blindness.

## **8. Following corneal disease and corneal surgery**

Secondary ocular hypertension can occur because of disorders of the cornea (the clear window at the front of the eye). Corneal infection, whether bacterial or viral, and corneal burns may cause inflammation in the eye (similar to uveitis) leading to raised intraocular pressure.

Many corneal conditions require the use of long-term eye drop steroids which can lead to sustained steroid response pressure elevation. This is commonly seen in patients who have undergone corneal grafts, where topical eye drop steroids are needed for many months to prevent the corneal graft from failing. If this cannot be treated with eye drops and the optic disc is showing glaucoma damage then glaucoma drainage surgery is usually recommended.

Some patients with complicated corneal problems may develop scarring adhesions between the iris and the trabecular meshwork (peripheral anterior synechiae); this also occurs in patients following multiple graft surgery. If the synechiae are extensive, the outflow of aqueous can be severely affected, leading to high intraocular pressure. In many cases, glaucoma drainage surgery may be required. Very rarely, patients with multiple failed corneal grafts may need to have an artificial keratoprosthesis (artificial corneas) inserted to allow them to see. Keratoprosthesis patients have a high risk of developing secondary glaucoma, with the additional problem that the pressure in eyes with artificial corneas cannot be measured. Such patients will require glaucoma drainage surgery (invariably tube implantation).

## 9. Iridocornealendothelial (ICE) syndrome

Iridocornealendothelial (ICE) syndrome is a rare disorder that can cause glaucoma in adults aged 30-50 years, more commonly in women. It is unilateral (occurring in only one eye) and is related to an abnormality of one of the cell layers of the cornea. ICE syndrome is associated with swelling of the cornea and acquired defects of the iris.

High pressure is caused by the formation of adhesions of the iris to the trabecular meshwork (peripheral anterior synechiae) reducing the outflow of aqueous. It can be difficult to control the pressure in such eyes using drops, so treatment will often require the implantation of a glaucoma drainage device (tube surgery).

## 10. Bleeding inside the eye

As mentioned in the section on trauma, blood cells in the anterior chamber can clog up the drainage channels and lead to high pressure. Blood in the vitreous cavity (vitreous haemorrhage – often occurring in proliferative diabetic retinopathy) can cause raised pressure by a similar mechanism.

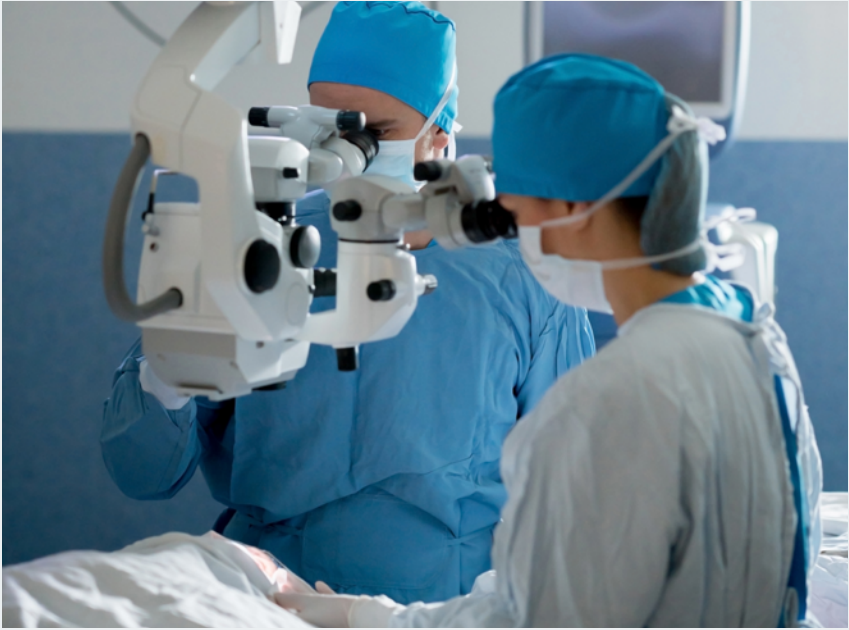## 11. Raised Episcleral Venous Pressure

This refers to conditions where there is raised pressure in the veins into which the aqueous drains. This can happen when there is an increase in pressure in the tissues of the eye socket (e.g. in the presence of an orbital tumour or thyroid eye disease), or abnormalities of the veins, or an abnormal link between the arteries and veins (a fistula). This high pressure restricts the outflow of aqueous and therefore causes high eye pressure.

## 12. Tumours

Occasionally tumours may develop in the eye. Tumours in the iris may involve the drainage angle and therefore reduce drainage outflow causing high eye pressure. A tumour in the ciliary body may push the peripheral iris forward, closing off the drainage angle. Large tumours in the back of the eye may push the lens forward, closing off aqueous passage through the pupil leading to a secondary pupillary block angle closure. Tumours may also cause new vessel formation, with the same effect as described in point 7.

# 03 Treatment



Specific interventions, such as cataract surgery, or lens removal or repositioning have been discussed for lens-related causes. The creation of a peripheral iridectomy for secondary angle closure in uveitis has also been discussed in the section about uveitic glaucoma.

Surgical or laser intervention needs to be considered if treatment to address the high pressure and underlying

cause are not successful enough. This is because there is a significant risk of vision loss unless the high pressure is definitively addressed. The most common surgical procedure undertaken for glaucoma (other than cataract surgery) is called trabeculectomy.

Trabeculectomy is usually quite successful in the management of uveitic glaucoma. However there is a high risk of trabeculectomy failure in other forms of secondary glaucoma such as neovascular (rubeotic) glaucoma, aphakic glaucoma and glaucoma related to retinal surgery (particularly if silicone oil has been used in the eye). In these cases, it is usually preferable to insert a tube shunt. This tube diverts aqueous from the anterior chamber to a plate secured to the rear part of the eyeball. From here, the aqueous can drain into the bloodstream. This differs from trabeculectomy where the aqueous collects in a 'bleb' nearer the front of the surface of the eye just below the upper eyelid. Compared to trabeculectomy, the tube procedure is less likely to cause scarring and therefore less likely to fail for certain secondary glaucomas.

There is a form of laser treatment called 'cyclodiode' or ciliary body ablation which can be very useful for treating some secondary glaucomas. The laser treatment works by reducing the production of aqueous by the ciliary body. The effect is usually temporary. It is often used in eyes that are painful and blind due to secondary glaucoma. It can, however, be very useful in eyes with good visual potential while other treatments are considered. It should

be avoided in people with uveitis as it can increase the degree of inflammation and can make the vision worse through accumulation of fluid at the macula.

A popular laser treatment for primary open angle glaucoma known as selective laser trabeculoplasty (SLT) is unlikely to work in most forms of secondary glaucoma. It is sometimes inadvisable in pigment dispersion syndrome and pseudoexfoliation as it can cause high pressure spikes post-laser; however experienced laser surgeons can safely and successfully use this treatment in patients with these conditions by using a lower amount of laser energy.

There are a number of newer microinvasive surgical glaucoma treatments that have become available to glaucoma surgeons. Whilst these show some promise in the management of ocular hypertension and primary open angle glaucoma, at the time of writing there is very little published evidence demonstrating their long-term effectiveness in secondary glaucomas.

# 04 Remember



If you have glaucoma in both eyes you must inform the DVLA.



Prescribed drops should be used as recommended by your specialist, on a daily basis unless and until otherwise informed.



If you develop side effects you are concerned about, you should inform your specialist as soon as possible.



# 05

## Questions you could ask your eye consultant

“

What type of secondary glaucoma do I have?

“

How does this differ from the other types of glaucoma?

“

What treatment will I be receiving?

# 06 Further help and information from Glaucoma UK

Glaucoma UK is here for anyone affected by glaucoma. For help and advice:

Call our telephone helpline:

**01233 64 81 70** (9.30am - 5.00pm Monday to Friday)

Email us with any worries or queries:

**helpline@glaucoma.uk**

Visit our website **www.glaucoma.uk** for information and advice. You can also order a range of free booklets online and use the user forum to ask questions and share experiences with other people living with glaucoma

Call us to find out if there is a glaucoma patient support group in your area.

# About Glaucoma UK

- We fund sight-saving research into the early detection and treatment of glaucoma
- We campaign to raise awareness of glaucoma so that no one loses their sight needlessly
- We provide support that helps people to live well with glaucoma

Each year in the UK over 11,000 people are diagnosed with glaucoma. We are passionate about supporting them and are committed to providing our services free of charge to anyone who needs them. It is only through the generosity of our supporters that we can do this.

## Help us save sight and fund research

- make a donation by calling 01233 64 81 64
- donate online at [glaucoma.uk](https://glaucoma.uk)
- become a member for £17.50 a year. Join online or call 01233 64 81 71

Your support will make a difference to people with glaucoma today and will protect future generations from unnecessary glaucoma sight loss.



The information in this leaflet was correct at the time of printing (printed 06/2020).

**Glaucoma UK**

Woodcote House  
15 Highpoint Business Village  
Henwood  
Ashford  
Kent TN24 8DH

**Phone:** 01233 64 81 64

**Email:** [info@glaucoma.uk](mailto:info@glaucoma.uk)

**[glaucoma.uk](http://glaucoma.uk)**

Whilst every step has been taken to compile accurate information and to keep it up to date, we cannot guarantee its correctness and completeness.

Glaucoma UK and the author cannot take responsibility if you rely solely on the information in this booklet. The information provided is designed as an addition to, and not a substitute for, professional advice from a qualified doctor or other healthcare professional, which will be tailored to a patient's individual circumstances.

Charity registered in England and Wales No. 274681  
and Scotland No. SC041550